

# Presenting Occlusion Disease in 3-D for Greater Case Acceptance



Don Reid, DDS

Occlusal disease is one the most destructive and neglected elements in dentistry, and it plays a major role in reducing the longevity of our finest restorative efforts.

It can present itself in the form of painful, clicking temporomandibular joints, sore facial muscles, headaches, tooth wear, tooth looseness, sensitivity, and tooth migration. It is a dominant factor in the fracture of restorations on posterior teeth.

Although a dentist may understand the cause and effect of these destructive forces, explaining these concepts to patients and their families can be very difficult. It is much easier to discuss the solution for caries or fractured teeth than it is to describe how excess wear is caused by a movement of the mandible from maximum intercuspation into and out of centric relation position. Likewise, interferences on the balancing or nonworking side during lateral excursions are difficult

*When the advantages of treating occlusal disease were understood using the power of visual learning, the patient immediately realized that his personal goals of improving his appearance and achieving a healthy dentition were within his grasp.*

enough for dentists to see and detect; this difficulty is only compounded when we try to explain these problems to patients.

Difficult or not, we are obligated to offer a treatment plan for the resolution of all disease categories that fall within our scope of healthcare service.

## CASE REPORT

A middle-aged male came into my practice wanting to replace tooth No. 24, which was missing due to trauma, and restore broken molar No. 31. His only request was that we not use gold on the molar as had been done in the past, but rather that we use some of the newer porcelain crowns he'd seen and heard about through the media that would match his existing coloration.

A preclinical interview was conducted, during which we discussed specific long-term goals and objectives. Full-mouth radiographs, 9 intraoral photographs (Canon Digital Rebel), panorex, and mounted study models (SAM 3 Articulator [Great Lakes Orthodontics]) in centric relation were taken. A complete examination was conducted evaluating the TMJ, muscles, periodontal structures, cancer evaluation, and occlusion. The tooth-by-tooth exam looking for excess wear, looseness, fractures, and caries was aided by the use of a dental operating microscope (Global Protégé).

## INITIAL FINDINGS

The patient's goal was to keep his natural teeth for a lifetime (Figure 1), and he expressed a desire for his dental team to help him achieve a more healthy and comfortable mouth.

The health history was unremarkable. The patient was aware of grinding his teeth during sleep, as he would wake on occasion with facial pain. The periodontal examination revealed a healthy mouth with a mild, localized gingivitis. The missing lower front tooth was recently removed and successfully grafted. There was mesial drifting of teeth Nos. 23 and 25.

Caries was incipient (DIAGNOdent [KaVo]) and confined to occlusal surfaces only. This patient had a very healthy mouth as it relates to the teeth and periodontal tissues. However, the signs of occlusal disease were everywhere and significant in nature. This was evidenced by the following findings: muscles were palpated and, on a scale from 1 to 10 with 10 being exceptionally tender, displayed a 6 on the belly of the masseters bilaterally. The anterior fibers of the temporalis were an 8 on the left and a 5 on the right. Both medial pterygoids were very painful upon minimal palpation. The TMJ had no pain upon palpation and had an early opening and late closing click upon full opening to 50 mm. There was no deviation on opening and normal ability to move the jaw side-to-side 10 to 15 mm. The Doppler auscultation (Great Lakes Orthodontics) examination was normal on rotation and revealed slight crepitus sounds upon translation.

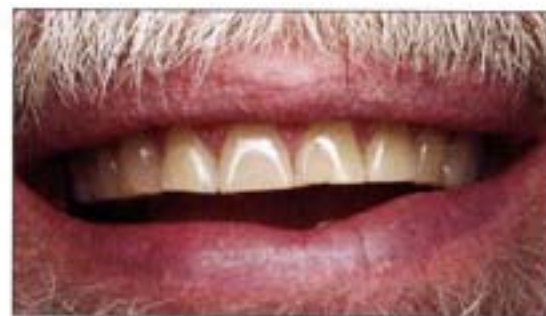

Figure 1. Natural smile taken before treatment.

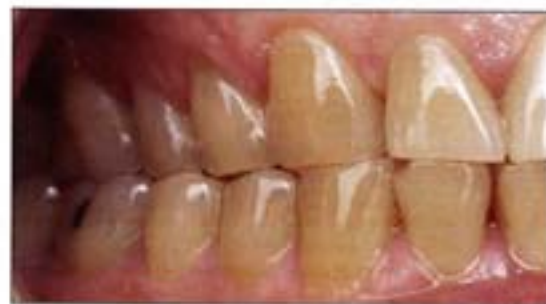

Figure 2. No canine guidance.

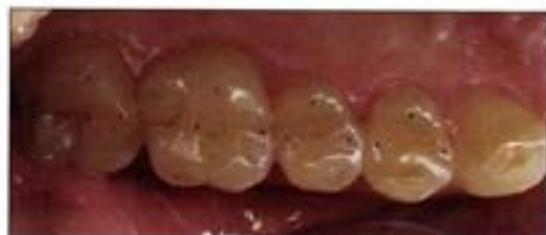

Figure 3. Patient's upper right arch showing severe attrition of cuspid and buccal cusps of all posterior teeth due to lack of anterior guidance. Small points indicate more ideal tooth contacts.

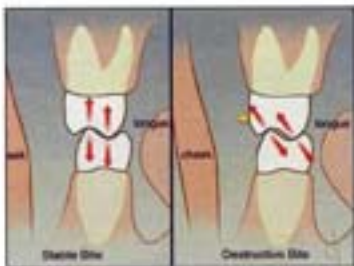Centric relation position was determined using bimanual manipulation, and the first tooth in contact was in fact the broken and loose molar No. 31. From CR there was a 2-mm forward slide into CO. The large wear facet on tooth No. 31 had its distal origin in CR when evaluated with thin articulating paper. Occlusal examination showed minimal yet sufficient separation of the posterior teeth in protrusive motion. There was group function with balancing interferences during lateral movements bilaterally (Figure 2).

Not surprisingly, given the findings above,

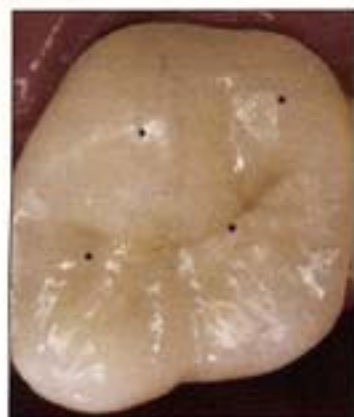*continued on page 84*

## Presenting Occlusion Disease...

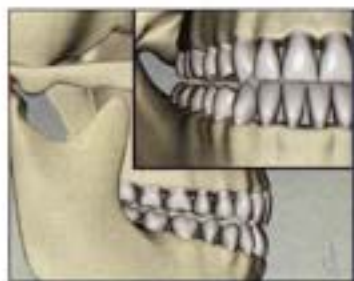
continued from page 83



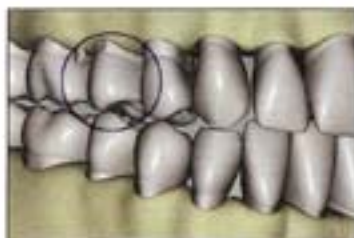**Figure 4.** Animation showing how proper tooth contacts are pinpoint on molars and directed toward the long axis of the roots versus contacts on inclines that move, wear, or fracture teeth.



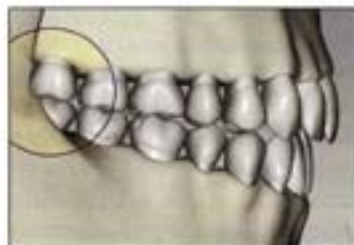**Figure 5.** Demonstrating how minimal the areas of contact are ideally.



**Figure 6.** Animation depicts desired effect with cuspid rise during lateral jaw movement.



**Figure 7.** Animation allowed me to wear down the canine cusp tip in real time and focus on the loss of back tooth separation. This shows the contact, movement, and possible abfraction that occurs.



**Figure 8.** By moving the mandible into CR and back to CO, the patient observed the impact on the most distal tooth in contact. Tooth movement causing open contacts, looseness, and reasons for fracture or sensitivity is demonstrated here.

the buccal cusp tips of all maxillary posterior teeth displayed wear facets into dentin (Figure 3). The maxillary first and second premolars had class 2 mobility, and there was pronounced recession on the facial surface of the first premolars.

This patient was doing more harm to his teeth due to the destructive forces of an unstable bite than from disease caused by bacterial origin. My intent was to help him appreciate the severity of his occlusal disease and see the need for a comprehensive treatment plan to address his needs. The patient was invited back for a treatment consultation.

## SEEING THE PROBLEM

I began the consultation by discussing my role in establishing ideal tooth contact (BiteFX software, Figure 4). Given his desire for a porcelain restoration instead of a gold one, the patient quickly grasped the importance of addressing his occlusal problems when shown a digital photo of the ideal versus actual contacts on his own teeth (Figures 3 and 5). I explained that this type of severe and improper contact would wear through gold but could fracture glass!

## ROLE OF FRONT TEETH

I then relayed an analogy of fence posts withstanding vertical forces but not doing well if repeatedly backed into by a pickup truck, so that the patient readily understood the idea of the back teeth hitting in ideal contact and the forces being directed vertically to accomplish stable occlusion. I watched the eyebrows rise as I showed him ideal canine guidance during lateral jaw movement using animations (Figure 6). The animation used to demonstrate how lack of canine guidance can harm rear teeth was extremely helpful for his treatment decisions (Figure 7). I then directed him to a previous picture (Figure 3) and observed as he acknowledged the magnitude of his newly discovered problem. When shown animations of tooth looseness caused by destructive forces (Figure 8), issues of mobility and wear were understood simultaneously.

## THE REMAINING AND CRITICAL CONCEPT

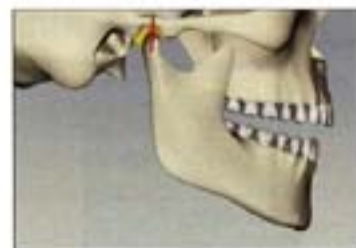Centric relation position of the TMJ during biting is the border position that allows the restorative dentist to "perfect and protect" the bite from destructive forces. Using BiteFX animations (Figures 9 and 10) the patient understood the source of his wear and the meaning of the initial tooth contact on tooth No. 31 (the slide). The beauty of distributing the force over the largest area possible to minimize stress (stress = force/area) was highlighted by reinforcing proper tooth contact as all teeth hit simultaneously (Figure 11).

## A WIN-WIN, NO-PRESSURE TREATMENT PLAN

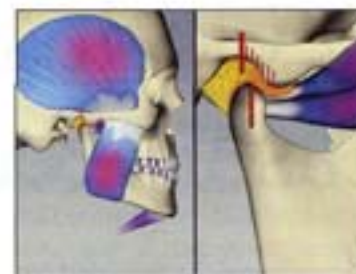
The treatment plan that met the original chief complaint included minimally invasive operative dentistry, a porcelain crown on the broken molar, placing an implant and implant-supported crown in site No. 24, and a full-coverage maxillary bruxism appliance (permissive type). He was informed the appliance would be mandatory during sleep and all other times when he was aware of clenching or grinding, ie, working in his shop, while driving, etc. I explained that this would be a lifelong requirement.

I then presented an alternative treatment option more consistent with his personal goals for natural-looking teeth combined with his desire to avoid the commitment to wearing an appliance. I explained that he could achieve built-in protection with a minimally invasive approach that included occlusal equilibration and all-ceramic veneers to restore anterior guidance. Together we viewed photos of his smile and decided that a minimum of 8 maxillary restorations would be acceptable aesthetically. At this point the patient made a decision to alter the color of his smile, whereas he originally wanted to have a crown to match his existing coloration. He understood that he may have additional elective veneers in the future and would still maintain the desired function to contain the destructive forces of his occlusal disease.

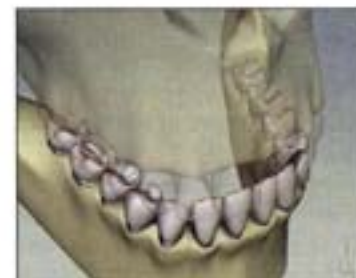The mutually understood treatment plan was thorough-



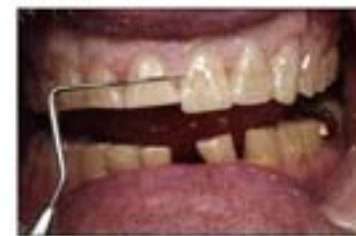**Figure 9.** The TMJ position in CR, jaw rotation, translation, as well as maximum intercuspation in harmony with CR are shown in this animation.



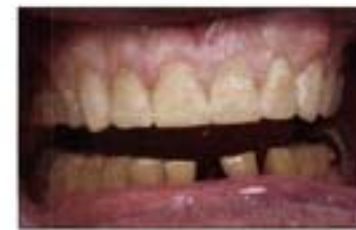**Figure 10.** The patient saw the effects of antagonistic muscles functioning simultaneously. Patient sees the muscles at war, and tooth wear is the cost of battle.



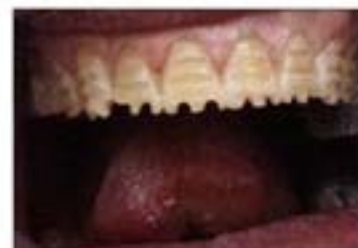**Figure 11.** Demonstration of how the dentist's job is to control destructive forces of occlusion. Patients see for themselves the concept of ideal tooth contacts on all teeth hitting evenly and simultaneously.



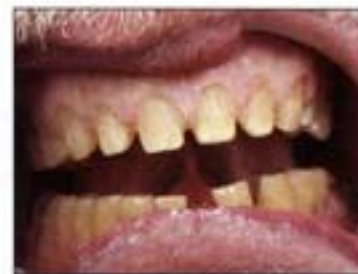**Figure 12.** Patient shown by 3-D mock-up on maxillary left side that the golden proportions for tooth size look like. Knowing the original tooth width allowed the author to restore to ideal length.



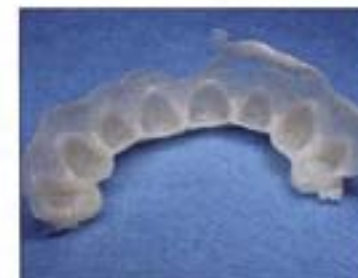**Figure 13.** The teeth shown here were presented to the patient for his approval. They were then polished and ready for a "test drive."



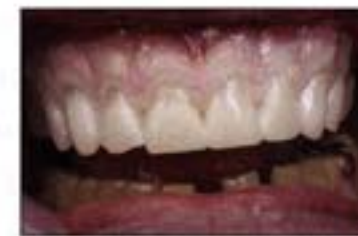**Figure 14.** The mocked-up teeth are prepared to minimal guidelines for ceramic veneers. There was no need to reduce incisal enamel, as that was removed by years of uncontrolled occlusal disease.



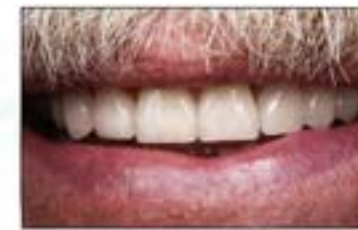**Figure 15.** Final preparations of tooth Nos. 5 to 12 prior to impression.



**Figure 16.** The provisional restorations were successfully removed in one piece from the elastic provisional matrix.



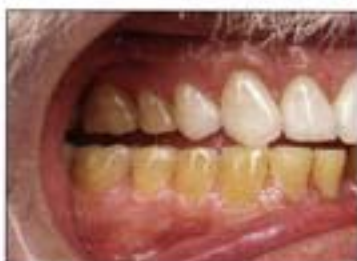**Figure 17.** Provisionals in the mouth prior to trimming, cementing, polishing, and repairing defects with LuxaFlow.



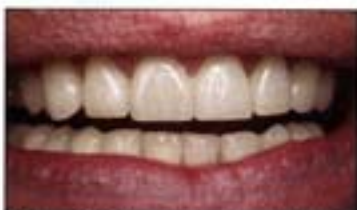**Figure 18.** Patient achieved his goals of controlling occlusal disease and having a more pleasing smile.

ly outlined, the cost was discussed, and the patient readily accepted it. The treatment plan included the following:

- Complete hygiene services necessary to attain optimal health.
- Equilibration to CR in



**Figure 19.** Canine guidance "built in" with final restorations. The patient opted for significant color change knowing tooth whitening and additional veneers were future elective options.



**Figure 20.** Later the patient elected to restore the lower anterior region with porcelain restorations to complement his upper teeth.

harmony with CO.

- Restoration of the upper anterior 8 teeth with feldspathic veneers to restore anterior guidance and create a more youthful and pleasing smile.
- Bone grafting and implant placement of missing tooth No. 24.
- All-ceramic restorations on the broken posterior molar and elective replacement of the gold molar, as well as restoration of all incipient caries with composite and preventive sealants on all other natural teeth.
- A future complimentary consultation to discuss tooth whitening and restorative options on the lower teeth visible in speech and smiling prior to the implant restoration on tooth No. 24.

#### GETTING STARTED

After achieving optimal oral health with the hygienist, an occlusal equilibration was performed simultaneously with an intraoral mock-up of the maxillary 8 teeth (Figures 12 and 13). The goal of having centric occlusion in harmony with centric relation combined with anterior guidance was attained. More importantly, the patient could take this new smile for a "test drive," evaluating for comfort, function, speech, interferences, and the look of the transformed bite.

After several months the new teeth did not show any evidence of wear, no noxious

habits had been developed, and the patient did not report any discomfort. The maxillary premolars became nonmobile.

#### FINAL PREPARATIONS

My examination confirmed that the mandible moved loosely and freely into centric relation and all teeth contacted ideally, ie, simultaneously upon guided or unguided closure. The teeth shape and position had been preapproved and test driven. Now the fun began.

Prior to preparation, impressions of the teeth were taken as a matrix for the provisional restorations. The teeth were minimally prepared (Figures 14 and 15) using Brasseler diamonds. Centric relation bite records were taken using Futar D (Roydent) as well as a face-bow transfer to a SAM 3 semiadjustable articulator. Final full-arch impressions were taken of both arches using vinyl polysiloxane (Splash! [Discus Dental]). This technique, combined with the use of the Axio-quick bite fork (SAM 3), elim-

inates the need for the dentist to either mount or pour the models. Stump shades as well as final restoration shades were determined, as the final restorations would be refractory feldspathic porcelain veneers.

The provisional restorations were fabricated chairside (Figures 16 and 17) using Luxatemp Fluorescence (Zenith/DMG) and bonded in place using LaxaFlow (Zenith/DMG). Models of the temporaries were taken using AlgiNot (Kerr Dental) to eliminate the need to pour models. A centric relation bite record of the temporaries using Futar D was recorded. Digital photos of the provisionals were provided for the lab.

The final restorations were placed using RelyX (3M ESPE; Figures 18 and 19).

#### CONCLUSION

This case is presented as one in progress. The lower implant placement was performed and, between writing this article and its publication, the patient elected to restore the lower anterior region with porcelain restora-

tions to complement his upper teeth (Figure 20). Additionally, he has expressed a desire to "add" one more upper restoration to enhance the appearance of his biggest smile.

My original intent was to help the patient achieve optimal oral health, comfort, and function, and to offer solutions to the obvious destruction occlusal disease had caused. His desire to have a more pleasing smile was solved in a conservative fashion, and it provided the solution to excess wear as well as tooth mobility and fracturing. The occlusal philosophy of functionally created anterior guidance in harmony with centric relation and centric occlusion allows the dentist to offer the very minimal dentistry needed to achieve desired health goals. Once stabilized, the patient has the luxury of proceeding with future care when it suits his personal desires and financial abilities.

This treatment plan was developed with the desires of the patient in mind. The visual presentation given to the

patient permitted him to understand the detrimental effects of occlusal disease and allowed him to "see for himself" the harmful effects of his current condition. When the advantages of treating this problem were understood using the power of visual learning (BiteFX), the patient immediately realized that his personal goals of improving his appearance and achieving a healthy dentition were within his grasp. ♦

**Dr. Reid** practices fee-for-service dentistry in Lake Tahoe, Calif. He believes dentistry is primarily a behavioral science. His philosophy, paperless office, and complete treatment planning contribute to client/practice success. In addition to being a recognized speaker, he is a founder of the Academy of Microscope Enhanced Dentistry, and is a member of the American Academy of Cosmetic Dentistry, International Congress of Oral Implantology, American Academy of Implantology, ADA, and the Organization for Conscious Sedation. Dr. Reid has been a behavioral consultant for Selection Research Institute (Lincoln, Neb). He can be reached at (530) 587-9560.

*Disclosure: Dr. Reid is co-developer of BiteFX software, a visual educational tool for explaining the causes and effects of occlusal disease.*